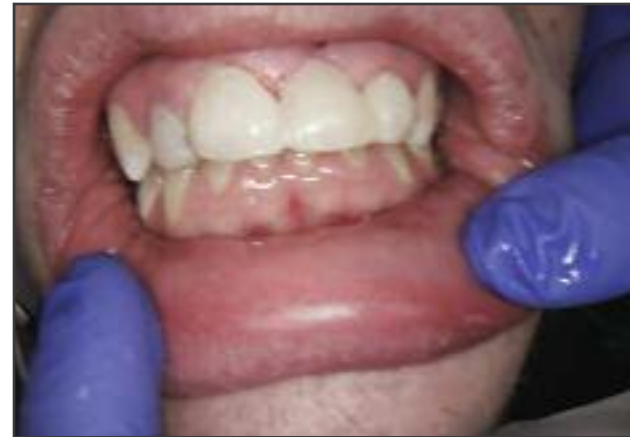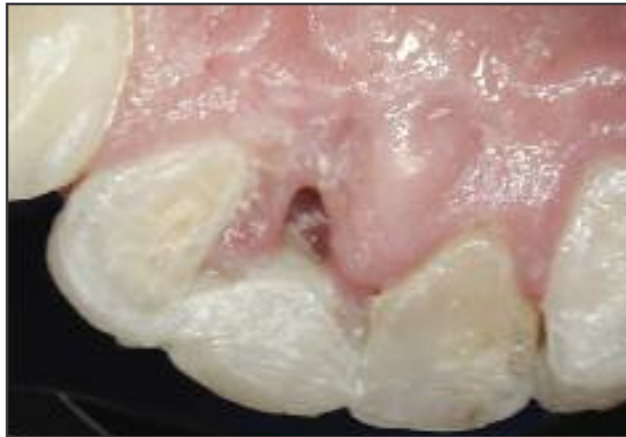

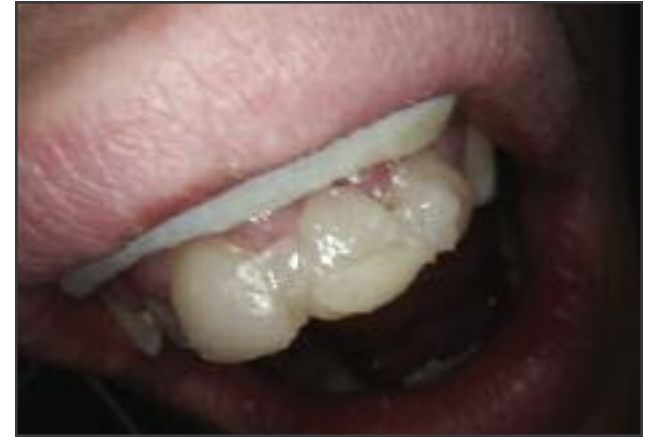
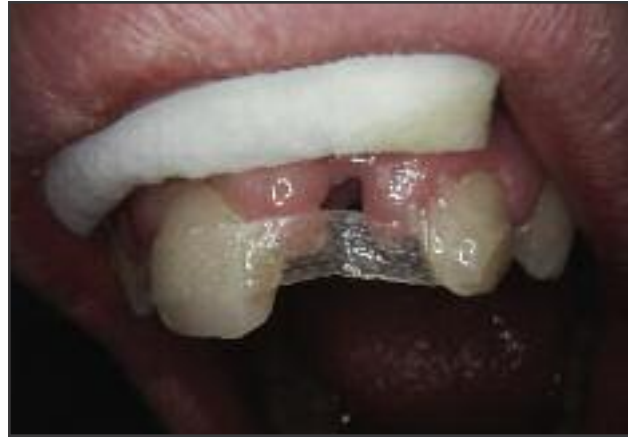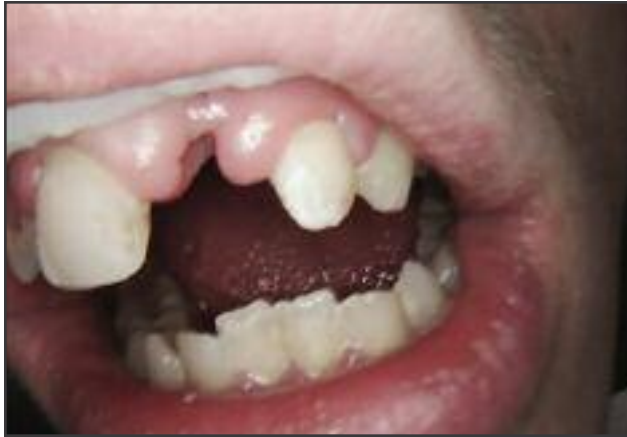Ribbon bridge with composite pontic. Ribbon placed on the facial.



Case and photos courtesy of Dr. Mark Mahn - Paris, Ontario, Canada